

Dear *****,

thank you for the kind information provided, as well as native MRI images of the mammary glands (without contrast) and with contrast for a radiological second opinion.

Clinical information:

The patient is worried about pain before menstruation, there is pain when squeezing. Light discharge from the nipple in May 2023. In April, Dostinex was prescribed to reduce Prolactin. In 2011, surgery to install breast implants in Antalya. Regular cycle (July 4, 2023 first DC) At the age of 66, her mother had surgery for endometrioid adenocarcinoma with metastases to the ovaries. Currently planning pregnancy, 40 years old (****1982)

Documents provided:

MRI images of the breast dated June 17, 2023 and a written conclusion of the MRI breast dated ****2021

MRI of the mammary glands with intravenous administration of contrast agent from **23:**

(Technical parameters: documented in the digital image provided).

Symmetrical mammary gland, with equal proportions of glandular and fatty components. Both mammary glands have implants installed prepectorally (above the pectoral muscles). The position of the implants is stable and normal. There are no signs of capsulitis (inflammation of the capsule around the implant) or rupture of the implants. In T2-weighted images, radial folds of varying sizes are visualized on both sides in the implants with a small amount of fluid (see attached images). After the administration of a contrast agent, pronounced motion artifacts are observed which complicate diagnosis. On the left at 5 o'clock there is a diffuse accumulation of contrast up to 2 cm. In the left axillary region 2 lymph nodes of 4 and 6 mm are visualized without dynamics compared to the written report from 12/21.

Conclusion:

- MRI without signs of malignancy
- On the left at 5 o'clock there is diffuse accumulation of contrast, requiring further examination

MR-Category II on the right and III on the left. Artifact level II.

Recommendations:

Mammography of both mammary glands in two projections.
MRI control after 3 months.

Best wishes,

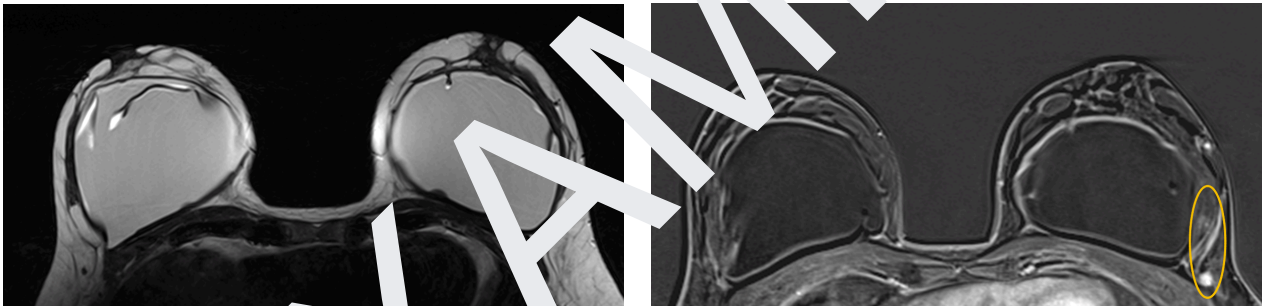
****2023

Dr. S. Popovich
Radiologist-mammologist



MRI - folds

Contrast and LN accumulation



Mammologicum GmbH
Account Number: 4349712038710655
Bank Name: Finom
IBAN Number: DE49110101015883621426
BIC/SWIFT: SOBKDEB2XXX